

"Case Report"**Evaluation of Root Canal Treatment in Chronic Periapical Abscess of Central Incisor****Yely Okta Mariza¹, Hartanti Putri Utami²**¹ School of Dentistry, University of Muhammadiyah Yogyakarta, Special Region of Yogyakarta, Indonesia² Department of Endodontic, Faculty of Dentistry, University of Muhammadiyah Yogyakarta, Special Region of Yogyakarta, Indonesia* Corresponding author, e-mail: yely.mariza@gmail.com**Abstract**

Introduction: trauma to the maxillary anterior teeth is often encountered, especially in teenagers. Severe trauma can result in pulp death and even periapical lesions if left untreated. This case report aims to evaluate periapical lesions in root canal treatment with anterior tooth fractures. Case report: A 21-year-old man came to RSGM UMY with complaints of a broken left front tooth. Teeth have been broken since early high school, around 16 years old. Clinical examination showed tooth 21 an Ellis class II fracture with caries in the fracture area in the mid and distal teeth. Apart from that, there was a vesicular lesion on the mucosa parallel to tooth 21 at 5 mm above the gingival margin, which was painless. Based on radiograph examination, a fracture of 1/3 of the crown is visible, there is a periapical lesion with a lesion size of approximately 5 mm, the lamina dura and periodontal ligament are broken in the apical 1/3. Case management: Root canal treatment was performed on tooth 21 to eliminate or reduce bacteria in the root canal. The sealer for treatment uses eugenol based. Results: The results showed that there was a significant change in the apical lesion at the beginning of the visit until the second control was carried out. Conclusion: Adequate root canal treatment can cure periapical lesions and bone regeneration in cases of chronic periapical abscess.

Keywords: root canal treatment, chronic periapical abscess, zinc oxide eugenol-based sealer.**INTRODUCTION**

Anterior tooth fractures are frequently reported cases.^{1,2} These fractures are usually caused by falls and impacts, the incidence rate varies from enamel to root fractures.^{1,3,4,5,6} It is not uncommon for trauma to occur resulting in death of the pulp so treatment is required.^{1,7}

Pulp necrosis or death of the pulp tissue is an irreversible condition of the pulp tissue characterized by damage to the pulp.⁷ Pulp necrosis that is not treated can result in infection in the root canal even up to the apical. Periapical lesions can be dental granulomas, radicular cysts, or abscesses.^{8,9} The incidence of abscesses is between 28.7% and 70.07%. There are 2 types of periapical abscess, namely chronic and acute. Acute conditions are characterized by symptoms of pain such as tenderness, spontaneous pain, abscess formation and tissue inflammation.⁹ Chronic conditions are characterized by an inflammatory response to infection and

pulp necrosis that occurs gradually, there is almost no pain or discomfort, and there is an abscess that drains discontinuously through the sinus tract. The radiograph usually shows a periapical radiolucent with an irregular diffuse border.¹⁰

One of the treatments for pulp necrosis is root canal preparation (RCT).¹ RCT is mainly used to eliminate or reduce bacteria in the root canal.¹¹⁻¹³ The mechanism involves cleaning and shaping. Cleaning is done by irrigation, while shaping is done by preparation using a file.^{7,14} However, the use of root sealer also has a big influence on the success of the treatment and in reducing periapical lesions.^{15,16} The aim of presenting the case study is to evaluate the results of root canal treatment in cases of chronic periapical abscess of central incisor teeth.

CASE REPORT

A 21-year-old male patient came to RSGM UMY on December 5 2022, with

the complaint that the patient's upper left front tooth was broken, causing discomfort. The tooth had been broken since I was in high school in grade 12 at the beginning of around the age of 16. It had been painful, but when it fell, the pain was like a throb and spontaneous pain when eating. Currently there are no complaints of pain and he has never been examined by a dentist, and there is no history of swelling in the tooth. Objective examination showed that tooth 21 was fractured up to 1/3 of the incisal and had changed yellowish color from the adjacent teeth, there was caries in the fracture area in the mid and distal palatal, blackish brown in color, depth of the dentin, sounding (-), percussion (+), palpation (-), CE (-). A vesicular lesion was seen on the labial gingiva in a round, reddish shape with clear boundaries with reddish edges, soft consistency, asymptomatic with a fistula assessment. (Figure 1. A, B). Periapical x-ray examination shows that on the crown there is a radiolucent area up to 1/3 of the incisal, there is one root with a single root canal, radiolucent, and relatively straight, the lamina dura is missing in the 1/3 of apical, the periodontal ligament is missing in the 1/3 of apical, the alveolar crest DBN (within normal limits), periapically there is a radiolucent area at the apical of tooth 21 in an irregular shape with diffuse borders measuring 5 mm, the radiodiagnosis is a fracture accompanied by a periapical abscess. (Figure 1. C). The patient was not suspected of having any systemic disease.

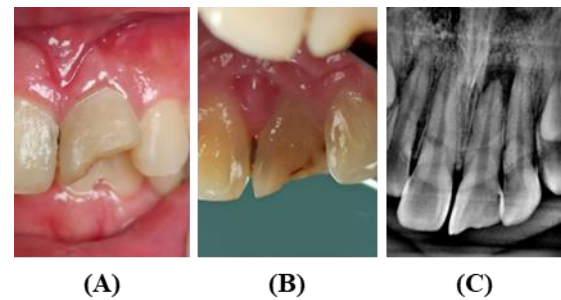


Figure 1. Objective Examination, Labial (A), Palatal (B), Radiographic Examination (C)

CASE MANAGEMENT

Based on the results of the examination carried out, the assessment of the case was a diagnosis of pulp necrosis accompanied by chronic periapical abscess with class II Ellis fracture and dentin caries and tooth discoloration. The treatment plan for managing tooth 21 is communication, information, and education, root canal treatment (RCT), class IV direct composite restoration, and control. The prognosis for treatment is good, because there is still a lot of remaining tooth tissue, there is an abscess in the tooth supporting tissue but it has not yet spread and it is hoped that it will heal as the treatment progresses, the patient is still easy so regeneration can still go well, the roots are relatively straight, there is no mobilization of the teeth, there are no systemic conditions that can affect treatment, the patient is quite cooperative and has a supportive socio-economic situation, and the patient has high motivation to be treated.

At the first visit, tooth 21 was isolated and opened access with a diamond round bur then continued with a diamendo bur and fissure bur (Figure 2. A). Pulp debridement was performed by root canal irrigation using 2.5% sodium hypochlorite and 17% EDTA. Root canal medication used cresophene, and the patient was scheduled for control 1 week later (Figure 2. B, C)

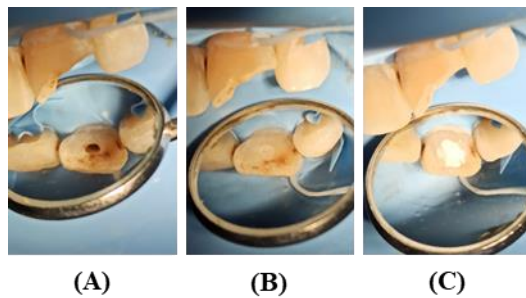


Figure 2. Open Access (A), Root Canal Medication (B), Temporary Filling (C)

At the next visit, the patient had no complaints, percussion and palpation examination were negative. Treatment carried out measuring the working length with an electronic apex locator and obtained a working length (WL) of 21.5 mm with a reference point on the coronal tooth parallel to the tooth axis. Initial apical file (IAF) with k-file and obtained a file size of 35. Root canal medication using cresophene, and the patient was scheduled for control 1 week later.

The next visit, root canal preparation (RCT) was carried out using the

step back method using a k-file with two stages, namely apical 1/3 preparation and coronal 2/3 preparation. The IAF was at #35 with a WL of 21.5 mm (Figure 3. A), while the Master apical file (MAF) was obtained at #50 with a WL of 21.5 and the final file #70 with a WL of 18.5 mm (Figure 4. E, F, G). During preparation, 2.5% sodium hypochlorite irrigation solution always floods the canal, with each change of file irrigation and recapitulation are carried out. Finally, the root canal walls were smoothed with h-file #50 WL 21.5 mm (Figure 4. H), then irrigated with 2.5% sodium hypochlorite and 17% EDTA. The irrigation solution was activated by agitation 100 times in 1 minute using gutta percha with a WL of 21 mm. The root canal was dried and medicated with pure calcium hydroxide mixed with glycerine and the patient was scheduled for control 1 week later.




Figure 3. IAF (A), MAF (B), End file (C), Root Canal Wall Smoothing (D), Root Canal Irrigation (E)

The next visit, bacterial examination and obturation were carried out. The root canal was finally irrigated with a solution of 2.5% sodium hypochlorite, saline and 2% chlorhexidine, then activated with 100x agitation in 1 minute using gutta percha with a WL of 21 mm. After it is dried, a bacterial test is carried out. Previously the results of the bacterial test were still (+), so the dressing was repeated but using cresophene. After 5 days, a retest was carried out and the result was (-). Obturation was continued by

determining the master apical cone (MAC) using gutta percha and obtained MAC number 55 with a WL of 21 mm. MAC was disinfected with 2.5% sodium hypochlorite for 1 minute. Sealer uses endomethasone mixed with eugenol, then applied to the root canal using red lentulo (Figure 4. A). MAC is applied to the root canal (Figure 4. B) followed by a gutta percha accessory, then condensed laterally using a finger spreader from largest to smallest number (Figure 5. C). Gutta percha is cut using an excavator heated in a spirit flame 1-2 mm below the

orifice, followed by cutting using a heated condenser while condensing vertically (Figure 5. D, E). The pulp chamber is cleaned using cotton pellets soaked in 2% chlorhexidine, dried and then lined with GIC type 3 (Fuji I) to cover the orifice as

well as a cover. Radiographs were taken to evaluate the root canal obturation (Figure 5. F), the results of the obturation were hermetic and there was no overfilling. The patient was instructed to come 1 week later for control.

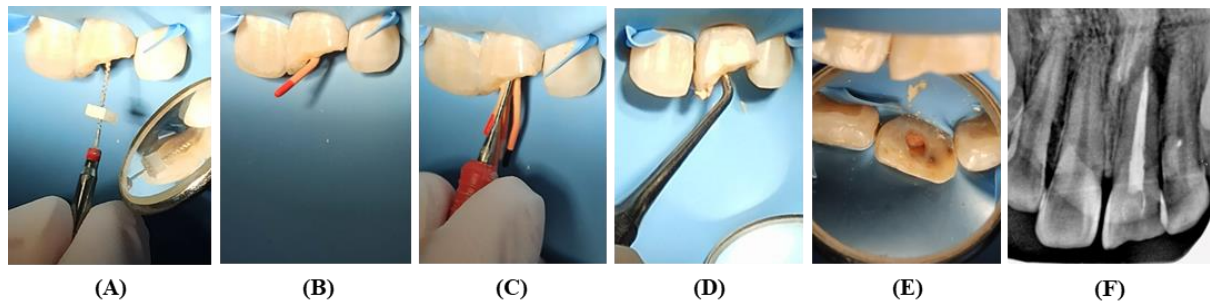


Figure 4. Sealar application (A), MAC (B), Obturation with lateral condensation and gutta percha assecory (C), Vertical cutting of gutta percha and condensation (D, E), Radiograph after root canal obturation (F)

One week of follow-up, radiographs, and permanent filling with class IV direct composite I were performed (Figure 5). It appears that the fistula in the gingival tissue has shrunk (Figure 5. A) and the radiograph results are still hermetic and there is no change from the previous visit (Figure 5. C).

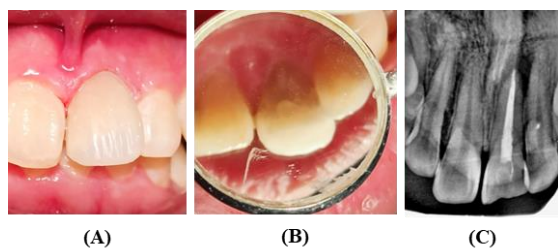


Figure 5. One week control. Labial (A), Palatal (B), Radiographic examination (C)

After 2 months of obturation, a radiograph was carried out to evaluate the periapical lesion (Figure 6. D). The results of the radiograph examination showed that the crown had a radiopaque area, the root canal had a radiopaque area totalling one straight shape with the number of root canals one within normal limits, the lamina dura disappeared in the distal apical 1/3, the periodontal ligament disappeared in the distal apical 1/3, the alveolar crest (within

normal limits), periapically there is a radiolucent area at the apical of tooth 21 in an irregular shape with diffuse borders measuring 2 mm, the radiodiagnosis is a fracture accompanied by a periapical abscess. The clinical picture also showed no fistula on the labial gingiva (Figure 6. A).

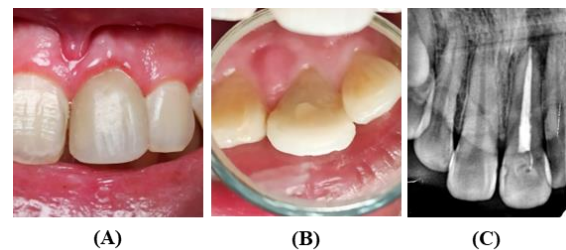


Figure 6. Two Month Control, Labial (A), Palatal (B), Radiograph Examination (C)

The patient has no complaints. Percussion and palpation examination were negative. Evaluation of periapical radiographs showed that there was a visible change in the size of the periapical lesion from the first visit with a lesion size of 5 mm to the second control at 2 months after obturation with a lesion size of 2 mm (Figure 7. A, B, C, D). In addition, the radiograph also shows changes in the color of the opacity of the periapical lesion.

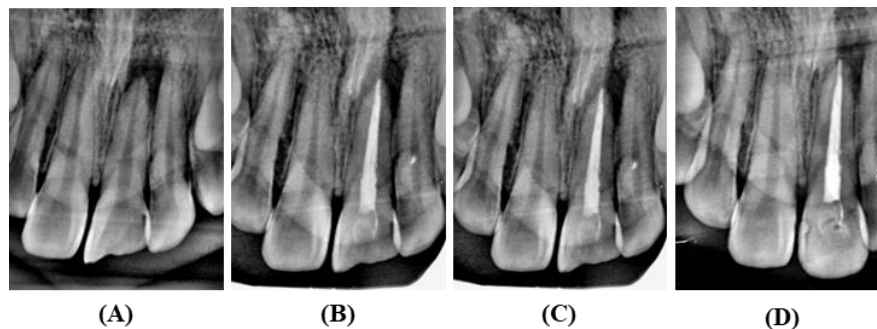


Figure 7. Before Treatment (A), After Obturation (B), One week control (C), Two month control (D)

DISCUSSION

The main goal of endodontic treatment is the elimination of microorganisms and infections by means of cleaning and shaping.^{11–13} There are various techniques for root canal preparation, one of which is the step back technique which is used in this case. This technique has two stages, namely root canal preparation from apical to coronal with gradual steps from small files and produces sharp and wide root canals.^{17–20} This treatment has quite long stages but is believed to minimize procedural errors.^{17,20} Treatment The step back technique also shows lower pain intensity compared to other techniques.²⁰ In addition, this technique has a denser obturation process because the condensation process with the finger spreader is close to the apex, thereby reducing leakage, but allows gaps to occur during condensation if it is inadequate.²¹

Irrigation uses sodium hypochlorite (NaOCl) 2.5%, Chlorhexidine (CHX) 2%, and Ethylenediaminetetra-acetic acid (EDTA) 17%. 0.5-5.25% NaOCl solution is the gold standard as an irrigation because it has antimicrobial capacity and can dissolve tissue strongly,^{22,23} but is toxic and can irritate periradicular tissue.^{22,24} CHX 2% can be used as root canal irrigation as a substitute for NaOCl because it has a broad spectrum antibacterial effect. In addition, CHX is effective on gram-positive bacteria compared to gram-negative bacteria and is low in toxicity and less irritating to the pulp than NaOCl, but does not have the property

of dissolving tissue.^{23,24} Although EDTA has limited antibacterial properties,²⁵ it has the property of dissolving inorganic tissue, so it is needed in the endodontic process to remove the smear layer from the results during preparation, dissolution of pulp tissue and remaining bacteria in the root canal.²⁶ The infection process can be assisted by activating the irrigation solution, one of which is using the manual dynamic activation (MDA) technique. This technique, apart from being economical, fast, and convenient for irrigation agitation at the end of preparation, also helps remove the smear layer and produces a clean root canal in the apical area.²⁷

The medicament ingredients used are calcium hydroxide (CaOH) and cresophene. CaOH is a recommended ingredient for dressings that have antimicrobial properties because it has a high pH content of around 12.5-12.8 and has the ability to reduce periapical inflammation.^{10,28,29,30} Cresophene is one of the ingredients that is often used before obturation.^{29,30} Cresophene contains parachlorophenol, dexamethasone, thymol, and camphor. Parachlorophenol has strong antibacterial properties, dexamethasone is anti-inflammatory, while thymol and camphor are antiseptic.^{21,29,30}

Cases with periapical lesions require a good irrigation agent or sealer to help eliminate bacteria in the root canal.^{11,12,15} This also helps in healing periapical lesions.^{13,15,16} The sealer used is zinc oxide eugenol-based sealer. This

material has a good antibacterial effect.^{13,14,31,32} Even though it is currently not widely used, the endomethasone sealer, namely zinc oxide eugenol-based sealer, is still able to compete with existing materials. Eugenol based sealer material is one of the most widely used standard sealers due to its long history of use.^{16,32} This material allows for treatment with limited materials and equipment in clinics that are far from good facilities.¹⁴

Obturation is carried out using the lateral condensation technique. Most scientific publications consider the lateral condensation technique to be the gold standard.³³ This technique is relatively simple and versatile and does not require expensive equipment compared to other techniques.^{22,33,34}

In this case, there was a significant change in the radiograph from a lesion size of 5 mm to 2 mm on the last radiograph with the radiolucent image starting to become opaque and only a few radiolucencies (Figure 7). Apart from that, there were no fistulas at the last visit when the control was carried out two months after obturation (Figure 6. A), and there were no subjective complaints from the patient. Adequate treatment can demonstrate good healing³⁵ with good bone regeneration on radiographs.¹⁰

CONCLUSION

Adequate root canal treatment using a step back preparation technique and zinc oxide eugenol-based sealer can cure periapical lesions and regenerate bone in cases of chronic periapical abscess. It is necessary to pay attention to each choice of tools and materials used so that they can produce good treatment and results.

REFERENCE

1. Departemen Gigi dan Mulut, Program Studi Sarjana Kedokteran Gigi dan

Profesi Dokter Gigi, Fakultas Kedokteran, Universitas Udayana, Bali, Indonesia, Sidiartha IFN, Wiswananta P P, Program Studi Profesi Dokter Gigi, Program Studi Sarjana Kedokteran Gigi dan Profesi Dokter Gigi, Fakultas Kedokteran, Universitas Udayana, Bali, Indonesia. Penatalaksanaan Fraktur Ellis Kelas III 11 dengan Pulpektomi dan Restorasi Mahkota Pasak. InterdentJKG. 2020 Dec 10;16(2):28–33.

2. Saikiran KV, Gurunathan D, Nuvvula S, Elicherla SR. Prevalence, Patterns and Pulp Vitality Testing of Traumatic Dental Injuries in Permanent Teeth: A Retrospective Study. 2023;
3. Mishra L, Kumar M. Rehabilitation of Fractured Tooth by a Custom Made Fibre Reinforced Composite Post. Int J Odontostomat. 2012;6(3):323–6.
4. Haryuni RF, Fauziah E. Penatalaksanaan fraktur Ellis kelas II gigi 11, 21 pada anak usia 9 tahun. IDGAI. 2018;1(1):10–6.
5. Imamullah AY. Perawatan Satu Kali Kunjungan Fraktur Ellis Kelas II pada Pasien Anak Perempuan Usia 11 Tahun (Laporan Kasus). Lembaga Pengembangan Publikasi Ilmiah dan Buku Ajar, Universitas Muhammadiyah Surakarta. 2020 Mar 17;2:11–7.
6. Sood H, Virk J, Pareek A. Traumatic Injuries of Teeth: A Review. ijhs. 2021 Jul 31;23–8.
7. Widyastuti NH, Nurhabibah G. Nonvital Root Canal Treatment of Necrotic Maxillary Left Lateral Incisor: A Case Report. ISETH. 2021;19–24.
8. Aeran H, Chandra S, Rautela M. Non-Surgical Management of A Periapical Abscess in A Adolescent Patient: A Case Report. International Journal of

- Oral Health Dentistry. 2017;3(4):240–3.
9. Pedraza JAQ, Nakagoshi MAA, Treviño JJF, Delgado IR, Cepeda EN, Meléndez RG. Endodontic Management of Acute Apical Abscess: A Case Report. *IJADS*. 2017;3(4):42–4.
 10. Indah D, Fibryanto E, Istanto leElline. Bone regeneration on chronic apical abscess after root canal treatment on left mandibular first molar: A case report. *Sci Dent J*. 2019;3(3):100.
 11. Poggio C, Lombardini M, Colombo M, Dagna A, Saino E, Arciola CR, et al. Antibacterial Effects of Six Endodontic Sealers. *Int J Artif Organs*. 2011 Sep;34(9):908–13.
 12. Arora S, Mir S, Gautam A, Batra R, Soni S, Lata K. Evaluation of Antimicrobial Efficacy of Root Canal Sealers against *Enterococcus faecalis*: A Comparative Study. *The Journal of Contemporary Dental Practice*. 2018 Jun;19(6):680–3.
 13. Duzyol E, Aydogdu S, Duzyol M, Akgul N. Antimicrobial Activity of Root Canal Sealers on Facultative Gram-positive Cocci. *Science and Education Publishing*. 2020;8(3):80–2.
 14. Giorgio C, Pasqualini ME, Giulia P, Pierangelo M, Luca DC, Franco R, et al. Endomethasone as Root Sealer: The Current State of Art: A Systematic Review Supported with Case Reports. *Glob J Oral Sci*. 2020 Feb 20;6(1):6–11.
 15. Suzuki P, de SOUZA V, Holland R, Gomes-Filho JE, Murata SS, Junior ED. Tissue Reaction to Endomethasone Sealer in Root. *J Appl Oral Sci*. 2011;19(5):511–6.
 16. Mahendra DA, Nindita Y, Wibowo GW, Fortuna G. Comparison of apical sealing ability between bioceramic and zinc oxide eugenol-based sealer during root canal treatment, in vitro. *Majalah Kedokteran Gigi Indonesia*. 2022 Jun 7;7(2):95.
 17. El-Kishawi M, Khalaf K. An Update on Root Canal Preparation Techniques and How to Avoid Procedural Errors in Endodontics. *TODENTJ*. 2021 Aug 24;15(1):318–24.
 18. Mehwish Munawwar, Muhammad Badar Munir, Mustafa Sajid. Comparison of Step-Down Versus Step-Back Hand Preparation Technique of Root Canals. *ashkmdc*. 2019 Mar 31;24(1):45–50.
 19. Gallottini L. Shaping of the Root Canal System: A Multistep Technique. *The Journal of Contemporary Dental Practice*. 2017 Sep;18(9):851–5.
 20. Agrawal A, Agrawal N, Biswas K, Vasisth D, Almutairi N, Alotaibi BB, et al. Evaluation of the Impact of Different Instrumentation Techniques on the Incidence of Postoperative Pain in Patients Undergoing Root Canal Treatment. *Cureus [Internet]*. 2023 Jul 31 [cited 2023 Nov 13]; Available from: <https://www.cureus.com/articles/169766-evaluation-of-the-impact-of-different-instrumentation-techniques-on-the-incidence-of-postoperative-pain-in-patients-undergoing-root-canal-treatment>
 21. Pasril Y, Marka IK. Management of Necrosis Teeth (Case Report). In: Permana I, Rochmawati E, editors. *Proceedings of the International Conference on Sustainable Innovation on Health Sciences and Nursing (ICOSI-HSN 2022)* [Internet]. Dordrecht: Atlantis Press International BV; 2022 [cited 2023 Nov 18]. p. 405–10. Available from:

- https://www.atlantispress.com/doi/10.2991/978-94-6463-070-1_51
22. Raoof M, Zeini N, Haghani J, Sadr S, Mohammadalizadeh S. Preferred Materials and Methods Employed for Endodontic Treatment by Iranian General Practitioners. *Iranian Endodontic Journal*. 2015 Jan 26;10(2):112–6.
 23. Ruksakiet K, Hanák L, Farkas N, Hegyi P, Sadaeng W, Czumbel LM, et al. Antimicrobial Efficacy of Chlorhexidine and Sodium Hypochlorite in Root Canal Disinfection: A Systematic Review and Meta-analysis of Randomized Controlled Trials. *Journal of Endodontics*. 2020 Aug;46(8):1032-1041.e7.
 24. Thakur DrV, Kaur DrM, Jamwal P, Thakur B. 2% Chlorhexidine in Root Canal Treatment: A Review. *J Current Med Res Opinion* [Internet]. 2020 Dec 27 [cited 2023 Nov 18];3(12). Available from: <http://cmro.in/index.php/jcmro/article/view/375>
 25. Mohammadi Z, Shalavi S, Jafarzadeh H. Ethylenediaminetetraacetic acid in endodontics. *Eur J Dent*. 2013 Sep;07(S 01):S135–42.
 26. Sato T, Fujimaki R, Suzuki J, Hamada N, Tani-Ishii N, Handa K. Bactericidal Effect of a Novel Alkaline EDTA Root Canal Cleaning Solution. *Eur J Dent*. 2021 Jul;15(03):546–50.
 27. Machtou PP. Manual dynamic activation technique. *Clin Dent Rev*. 2018 Nov;2(1):21.
 28. Ba-Hattab R, Al-Jamie M, Aldreib H, Alessa L, Alonazi M. Calcium Hydroxide in Endodontics: An Overview. *OJST*. 2016;06(12):274–89.
 29. Anggono FD, Kuswandari S. Comparison of antibacterial activity inhibitory of black cumin (*Nigella sativa*) oil, Cresophene®, and Calcium hydroxide. *Padjadjaran J Dent* [Internet]. 2017 Mar 31 [cited 2023 Nov 18];29(1). Available from: <http://jurnal.unpad.ac.id/pjd/article/view/11667>
 30. Pasril Y. Perawatan Saluran Akar pada Gigi Incisivus Sentral dan Lateral Maksila dengan Perbedaan Status Pulpa: Laporan Kasus. *di*. 2017;6(1). doi:10.18196/di.6174
 31. Manuaba IBPP, Prasetya MA, Rahaswanti LWA, Audina PI. Chemical Burn On Children Patient Due to Iatrogenic of Cresophene During Root Canal Treatment. *Indonesian Journal of Dentistry*. 2023 Aug 31;3(2):16.
 32. Ahamed T, R V G. Comparative Effect of Commercially Available Endodontic Sealers Against *Enterococcus faecalis*. *Int J Pharm Sci Rev Res*. 2017;44(2):186–7.
 33. Jeanneau C, Giraud T, Milan JL, About I. Investigating unset endodontic sealers' eugenol and hydrocortisone roles in modulating the initial steps of inflammation. *Clin Oral Invest*. 2020 Feb;24(2):639–47.
 34. Silva-Herzog D, Monroy E, Méndez V, Maia SMAS, Júnior PM, Oliva R. Fluid-Transport Evaluation of Lateral Condensation, GuttaCore™ and Continuous Wave of Obturation Techniques. *RSBO*. 2017 May 4;13(3):171.
 35. Bhandi S, Mashyakh M, Abumelha AS, Alkahtany MF, Jamal M, Chohan H, et al. Complete Obturation—Cold Lateral Condensation vs. Thermoplastic Techniques: A Systematic Review of Micro-CT

- Studies. Materials. 2021 Jul
18;14(14):4013.
36. Mustafa M. Evaluating the Quality of
Root Canal Obturation Performed by
Undergraduate Dental Students: A
Retrospective Clinical Study. World
Journal of Dentistry. 2022 Jan
31;13(2):133–7.